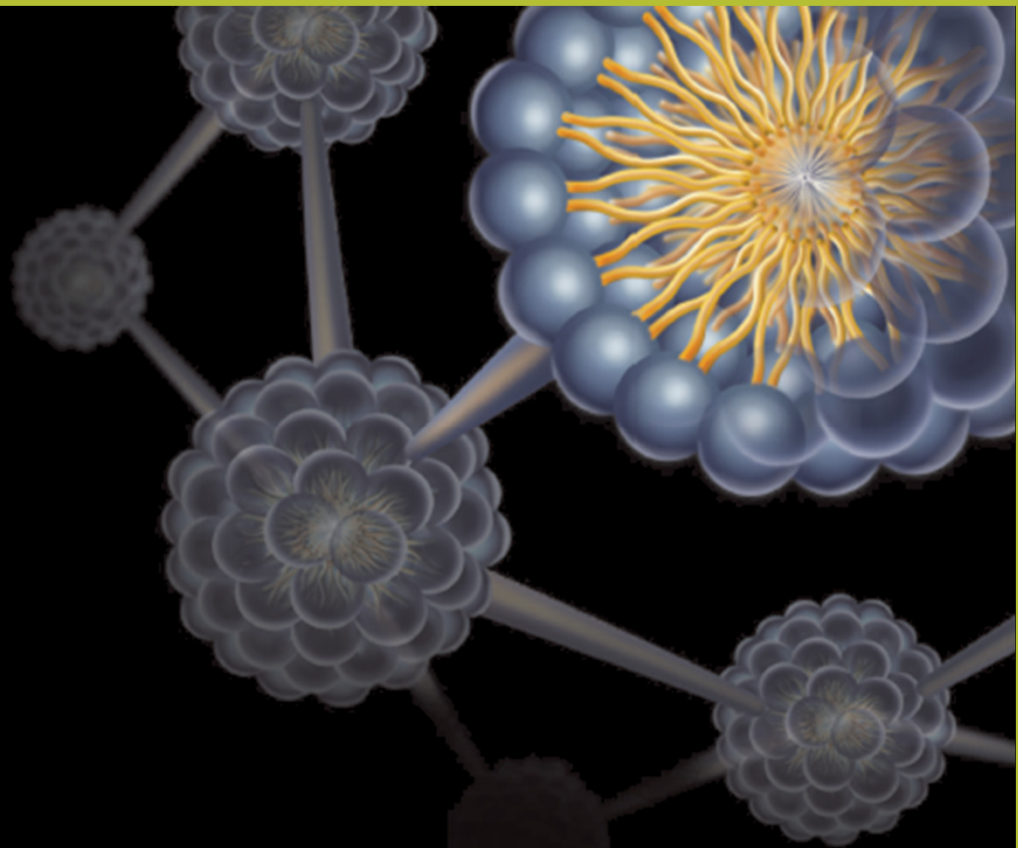




PLUROGEL[®]
Micelle Matrix Technology™



CASES WITH PLUROGEL

RESEARCH AND CASE STUDIES

Research

- More than 30 published articles
- Biggest study with 1036 patients in Europe
- More than 14.000 treated patients



PluroGel® Bibliography

1. Yang Q, Schultz GS, Gibson D. A Surfactant-Based Dressing to Treat and Prevent Acinetobacter Biofilms. *Journal of Burn Care & Research*. 2014. <https://doi.org/10.1093/bjcr/nbt041>. Abstract: <https://academic.oup.com/bjcr/advance-article-abstract/doi/10.1093/bjcr/nbt041/4693766>
2. Ferrellet SL, Mayer D, Makone M, Swanson T, Gibson D, Schultz G. Surfactants and their role in wound cleansing and biofilm management. *J Wound Care*. 2017 Nov 2;28(11):680-690. doi: 10.1177/0898010117311400. Abstract: <https://www.ncbi.nlm.nih.gov/pubmed/29311752>
3. Beilert CR. Case series of 18 patients with lower extremity wounds treated with a concentrated surfactant-based gel dressing. *Journal of Vascular Nursing*. 2017 Sept. In Press. Abstract: <http://www.scienceirect.com/science/article/pii/S1062003017301164>
4. Ferrellet SL, Mayer D, Salisbury AM. Efficacy of a surfactant-based wound dressing on biofilm control. *Wound Repair Regen*. 2017 Aug 30. doi: 10.1111/wrr.12581. [Epub ahead of print] Abstract: <https://www.ncbi.nlm.nih.gov/pubmed/28857343>
5. International Wound Infection Institute (IWII) Wound Infection in Clinical Practice: Principles of best practice. *Wounds International*. Nov 2016. Full article: <http://www.woundinfectioninstitute.com/wp-content/uploads/2017/03/IWII-Wound-Infection-in-clinical-practice.pdf>
6. Jeong S, Schultz GS, Gibson DJ. Testing the influence of surfactant-based wound dressings on proteinase activity. *Int Wound J*. 2016 Dec 8. doi: 10.1111/iwj.12697. [Epub ahead of print] Abstract: <https://www.ncbi.nlm.nih.gov/pubmed/27913732>
7. Yang Q, Larone C, Fortis AD, Della Porta AC, Schultz GS, Gibson DJ. A surfactant-based wound dressing can reduce bacterial biofilms in a porcine skin explant model. *Int Wound J*. 2016. doi: 10.1111/iwj.12619. Abstract: <https://www.ncbi.nlm.nih.gov/pubmed/27212453>
8. Bodehean GT, Smith SL, Thacker JD, Edgerton MT, Ertel RF. Mechanical cleansing of contaminated wounds with a surfactant. *Am J Surg*. 1975 Mar;129(3):241-5. Abstract: <http://www.ncbi.nlm.nih.gov/pubmed/1111965>
9. Bakaran H, Toner M, Yarmush ML, Berthiaume F, Polosamer-188 Improves Capillary Blood Flow and Tissue Viability in a Cutaneous Burn Wound. *J Surg Res*. 2001 Nov;101(1):56-61. Abstract: <https://www.ncbi.nlm.nih.gov/pubmed/11675555>



PluroGel® Bibliography

10. Lee RC, River LP, Pan FS, Ji L, Wolmann R. Surfactant-induced sealing of electroporabilized skeletal muscle membranes in vivo. *Proc Natl Acad Sci U S A*. 1992 May 15; 89(10): 4524-4528. Abstract: <http://www.ncbi.nlm.nih.gov/pmc/articles/PMC49116/>
11. Natori RM, Athanasiou KA. P188 reduces cell death and TGF- β reduces GAG release following single-impact loading of articular cartilage. *J Biomech Eng*. 2008 Aug;130(4):041012. doi: 10.1115/1.2939566. Abstract: <http://www.ncbi.nlm.nih.gov/pubmed/1860445>
12. Lee RC, Hanig J, Mathews KL, Myerov A, Chen CT. Pharmaceutical therapies for sealing of permeabilized cell membranes in electrical injuries. *Ann N Y Acad Sci*. 1999 Oct 30;888:266-73. Abstract: <http://www.ncbi.nlm.nih.gov/pubmed/10845819>
13. Maslankin SA, Hu G, Lee KY. Membrane sealing by polymers. *Ann N Y Acad Sci*. 2005 Dec; 1066: 310-20. Abstract: <http://www.ncbi.nlm.nih.gov/pubmed/16533934>
14. Schomka JR. A review of block polymer surfactants. *Journal of the American Oil Chemists' Society*. 1977; 54(9):120-124. Abstract: <http://link.springer.com/article/10.1007/bf02629435>
15. Hunter RL, Luo AZ, Zhang F, Kozar RA, Moore FA. Pluosamer 188 inhibition of ischemia/reperfusion injury: evidence for a novel anti-apoptotic mechanism. *Ann Clin Lab Sci*. 2010 Spring;40(2):125-25. Abstract: <http://www.ncbi.nlm.nih.gov/pubmed/20451692>
16. Curry DJ, Wright DA, Lee RC, Kang UJ, Frim DM. Surfactant pluosamer 188-related decreases in inflammation and tissue damage after experimental brain injury in rats. *J Neurosurg*. 2004 Aug; 101(2 Suppl):95-6. Abstract: <http://www.ncbi.nlm.nih.gov/pubmed/16206978>
17. Gu JH, Ge JB, Li M, Yu HD, Wu F, Qin ZH. Pluosamer 188 protects neurons against ischemia/reperfusion injury through preserving integrity of cell membranes and blood brain barrier. *Acta Otolaryng*. 2013 Apr 16; 133(4):614-61. doi: 10.3171/journal.pone.0061641. PMID: 23311373. Abstract: <http://www.ncbi.nlm.nih.gov/pubmed/23613890>
18. Bichenough SA. Topical Pluosamer-188 Improves In Blood Flow after Thermal Injury. Presented at Southeastern Society of Plastic and Reconstructive Surgeons Conference. 2007.
19. Birchough SA, Bodehean GT, Morgan RJ, Peirce SM, Katz AI. Topical pluosamer-188 improves blood flow following thermal injury in rat mesenteric microvasculature. *Ann Plast Surg*. 2008 May; 60(5):544-8. doi: 10.1097/APA.0b013e318161661. Abstract: <http://www.ncbi.nlm.nih.gov/pubmed/18434836>



PluroGel® Bibliography

20. Hanig J, Zhang D, Canaday DJ, Beckert MA, Azumian KD, Weischaus BA, Lee RC. Surfactant sealing of membranes permeabilized by ionizing radiation. *Radiat Res*. 2000 Aug; 154(2):171-7. Abstract: <http://www.ncbi.nlm.nih.gov/pubmed/10931689>
21. Cassino R. A New Dimension in Wound Care. Presented at EWMA. 2009; Helsinki, Finland.
22. Connor-Sallard PAJ. Understanding and managing burn pain: Part 2. *Am J Nurs*. 2009 May;109(5):54-62. Abstract: <http://www.ncbi.nlm.nih.gov/pubmed/19414907>
23. Multi-Center Clinical Results with PluroGel PSD in Chronic Wounds. Presented at a Satellite Symposium during EWMA 2012 in Vienna, Austria.
24. Bradbury S. Experiences of using PluroGel PSD on Chronic Leg Ulcers. Presented at EWMA. 2013.
25. Mustafi D, Smith CM, Makinen MW, Lee RC. Multi-block pluosamer surfactants suppress aggregation of denatured proteins. *Biochim Biophys Acta*. 2008 Jan;1780(1):7-15. Epub 2007 Sep 12. Abstract: <http://www.ncbi.nlm.nih.gov/pubmed/17951011>
26. Lee RC, Deepa F, Guo L, Batala P, Kuo A, Thyagarajan P. Surfactant copolymers prevent aggregation of heat denatured lysozyme. *Ann Biomed Eng*. 2006 Jul;34(7):1190-200. Epub 2006 Jun 20. Abstract: <http://www.ncbi.nlm.nih.gov/pubmed/16736193>
27. Bhandari KH, Neeva M, Kim JA, Yoo BK, Woo JS, Lyoo WS, Lim HT, Choi HG, Yong CS. Preparation, characterization and evaluation of coagrate Q10 binary solid dispersions for enhanced solubility and dissolution. *Biol Pharm Bull*. 2007 Jun;55(6):1173-6. Abstract: <http://www.ncbi.nlm.nih.gov/pubmed/17541177>
28. Chakshi RJ, Zia H, Sandhu HK, Shah NH, Malik WA. Improving the dissolution rate of poorly water soluble drug by solid dispersion and solid solution: pros and cons. *Drug Deliv*. 2007 Jan;14(1):31-45. Abstract: <http://www.ncbi.nlm.nih.gov/pubmed/17107029>
29. Turilli R, Piel G, Delattre L, Scaila S. Solid lipid microparticles containing the sunscreen agent, octyl-dimethylammonioacetate: effect of the vehicle. *Eur J Pharm Biopharm*. 2007 Jun;64(3):483-7. Epub 2007 Feb 28. Abstract: <http://www.ncbi.nlm.nih.gov/pubmed/17407009>



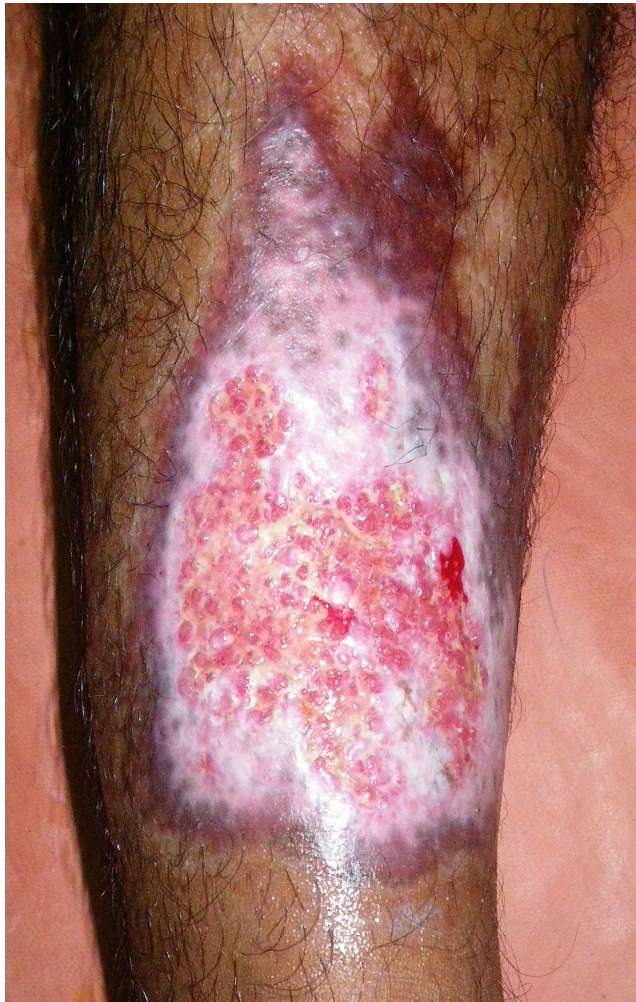PluroGel® Bibliography

30. Park SH, Kwon JJ, Choi HG, Park BC, Lee YS, Jeong TC, Jin CH, Oh YK, Kim JA. Pluosamer 188 and polyvinyl alcohol-based rectal suppository enhances antitumor effect of 5-Fluorouracil in mice. *Biol Pharm Bull*. 2006 May;29(5):1060-3. Abstract: <http://www.ncbi.nlm.nih.gov/pubmed/16651748>
31. Bekturova EV, Kabanov AV. Pluronic block copolymers: evolution of drug delivery concept from inert macromolecules to biological response modifiers. *J Control Release*. 2008 Sep 10;130(2):98-106. doi: 10.1016/j.jconrel.2008.04.013. Epub 2008 Apr 24. Abstract: <http://www.ncbi.nlm.nih.gov/pubmed/18754704>
32. Snook S, Rajwa B, Robinson JF. Characteristics and Dynamics of Bacterial Populations within Pluosamer Hydrogel Biofilm Constructs. Presented by Purdue University Cytometry Laboratories.
33. Technical Data Sheet. Prevention and Efficacy Against Pre-formed Biofilm TDS 6, Inovotech, 2008.
34. Stewart PS, Costerton JW. Antibiotic resistance of bacteria in biofilms. *Lancet*. 2001 Jul 14;358(9276):132-4. Abstract: <http://www.ncbi.nlm.nih.gov/pubmed/11663434>

BURN WOUNDS

Chemical Burn Case study

Burn Wounds

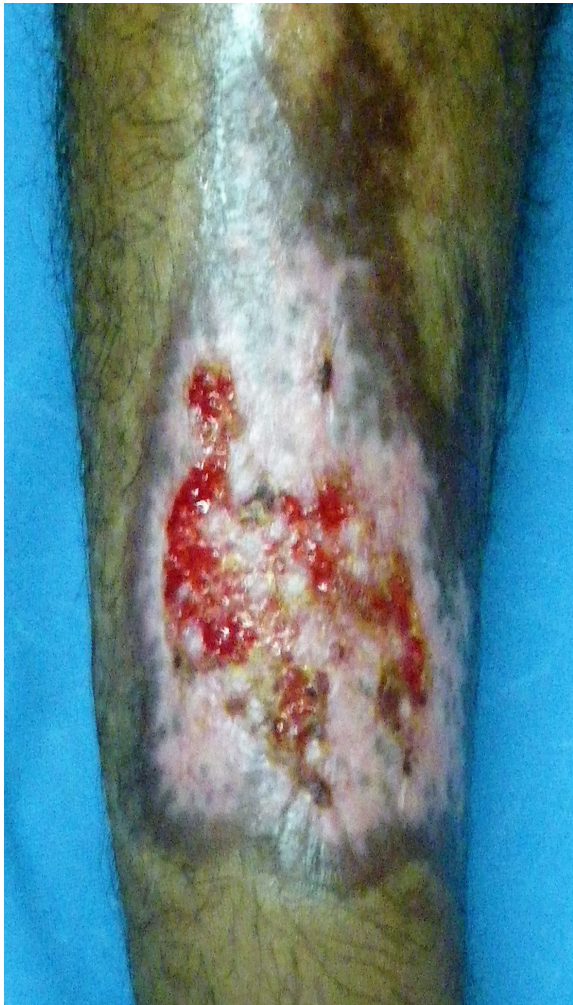

- » Six weeks post injury
- » Chemical burn
- » Non healing
- » Poor wound bed colour
- » Proteinase exudate present
- » Previous treatment – acticoat, jelonet, gauze swab and crepe bandage

Lt Col Prof Steven Jeffery
Burns & Plastics Consultants
Queen Elizabeth Hospital, Birmingham

Chemical Burn Case study

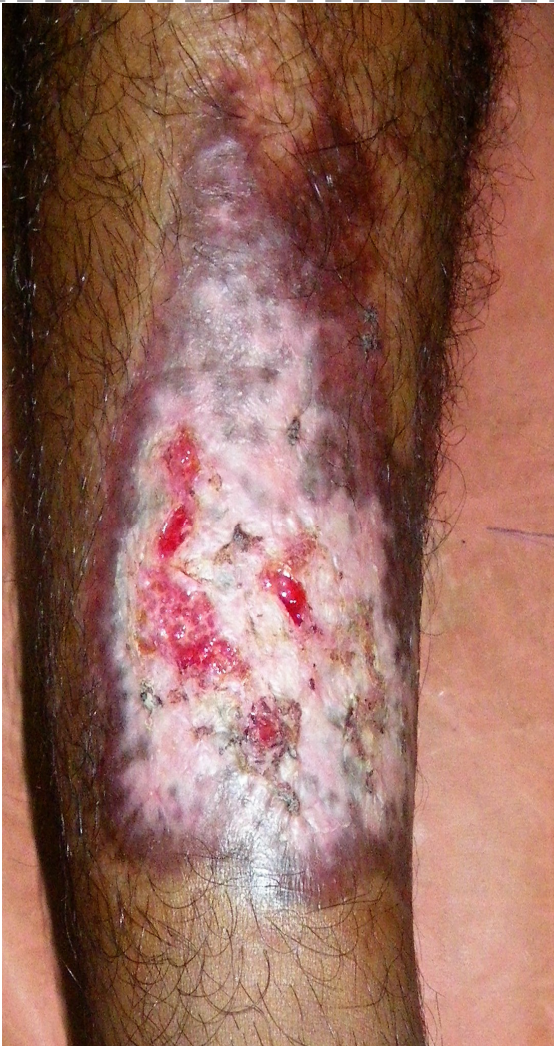Burn Wounds



- » Three days post Plurogel treatment
- » Epithelialisation occurring
- » Clean wound bed for healing
- » Wound margins dramatically reduced

Chemical Burn Case study

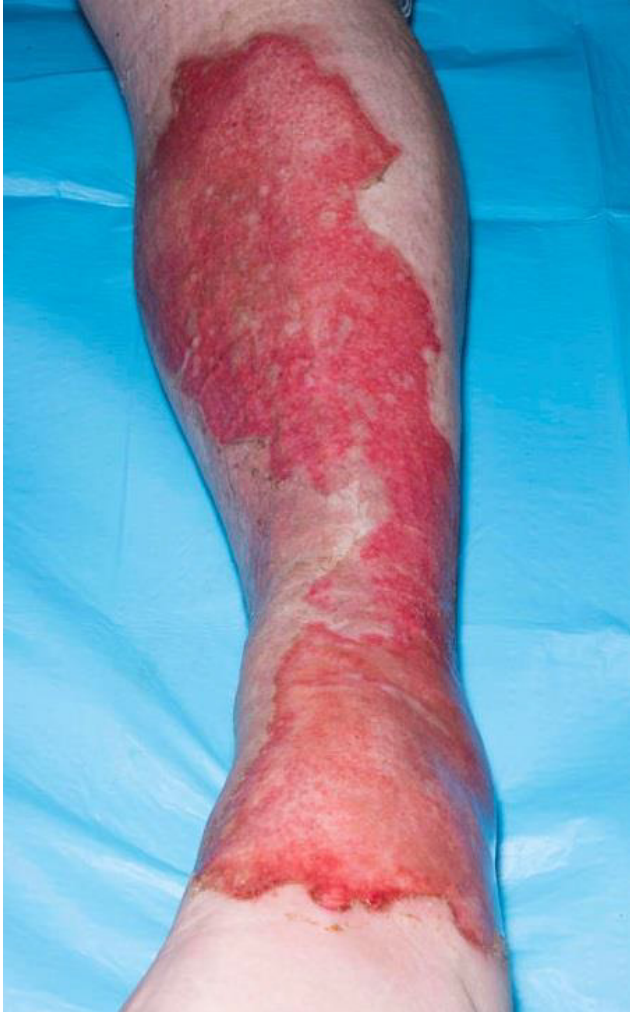Burn Wounds



- » Six days post Plurogel treatment
- » Further reduction in wound margins
- » Almost complete healing achieved
- » Patient did not attend for his next appointment. When this was followed up, it was because the wound had completely healed and the patient was discharged from clinic.

Flame Burn Case Study

Burn Wounds



Male Late 20s

Flame Burn to lower limb from a barbeque

Plurogel applied to gauze swab and applied to wound with jelonet.

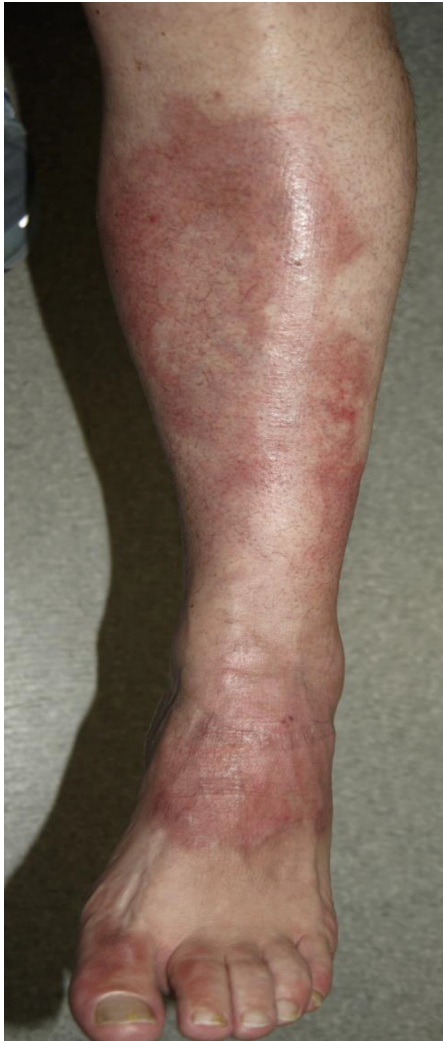Bandaged to secure.

Treated at outpatients clinic 3 times per week

Lt Col Prof Steven Jeffery
Burns & Plastics Consultants
Queen Elizabeth Hospital, Birmingham

Flame Burn Case Study

Burn Wounds

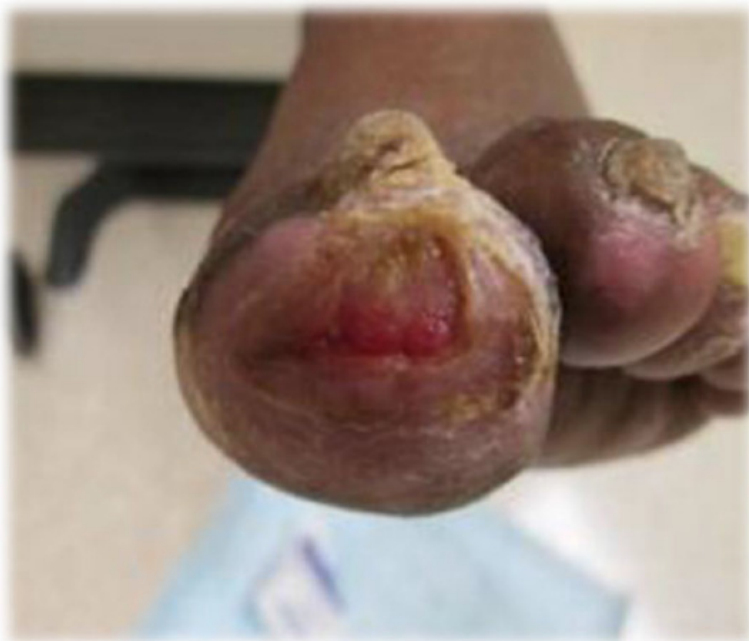

After 2 weeks of treatment the patient was discharged with complete healing and minimal scarring.

Toe Burn

Age 61, Toe burns

Day 1:



Day 14:

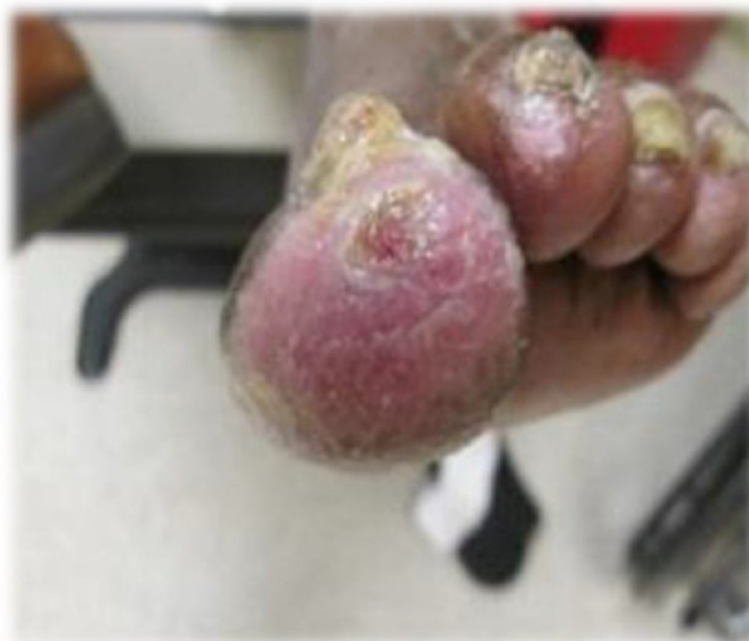
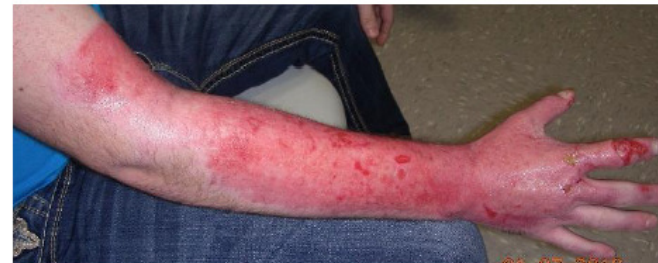
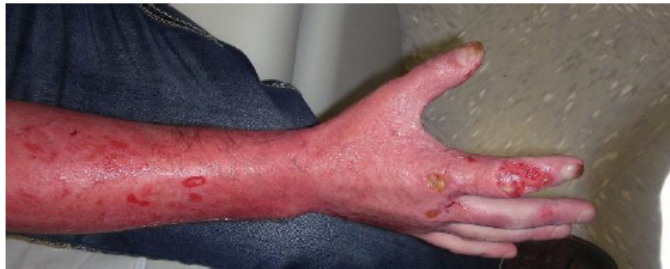Photo Courtesy of:
Catherine Ratliff, PhD, NP, CWOCN
University of Virginia Health System -- Charlottesville, VA

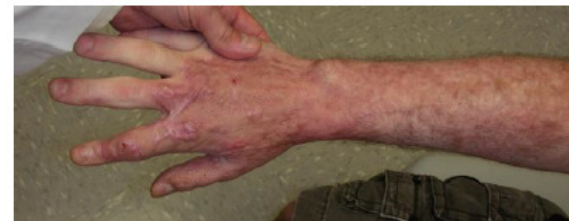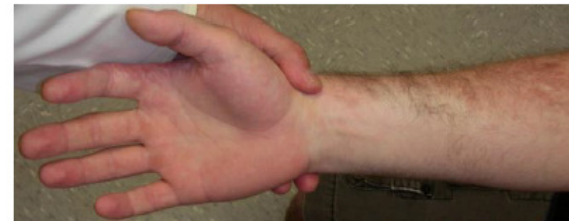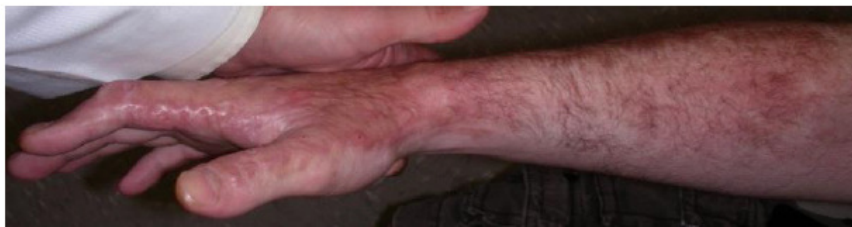Grease Burn

Age 26, Grease Fire to arm and hand

Day 1:



Day 90:

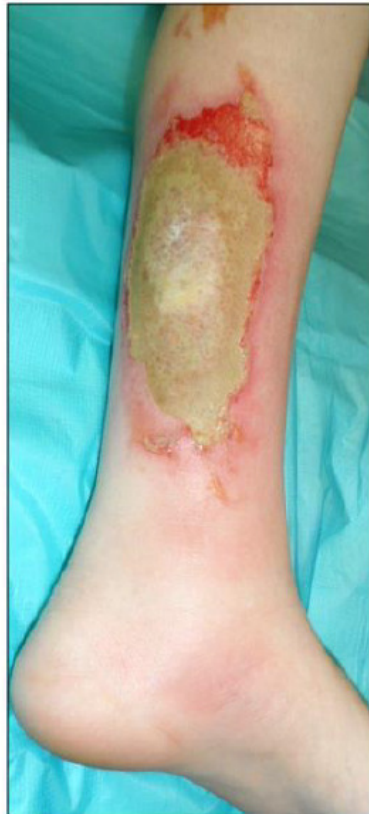

Photos Courtesy of:
Farid Mozaffari, MD, FACS
Marshall University Huntington, VA

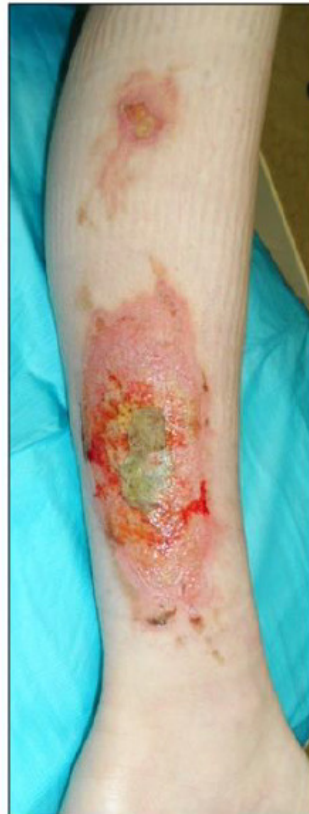Flame Burn

Burn Wounds

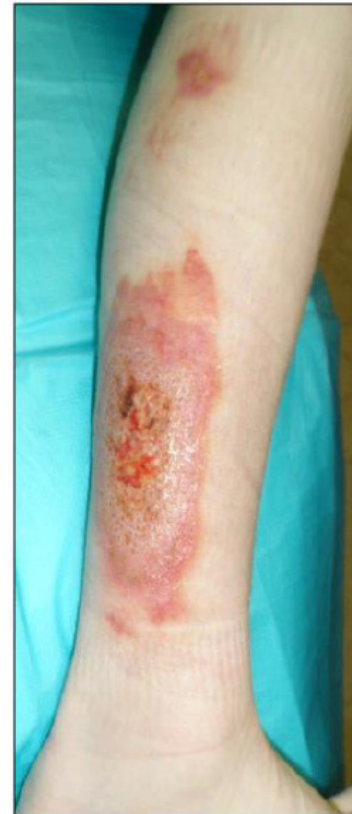Age 22, brush fire. Presented 8 days post burn.



Day 1



Day 7



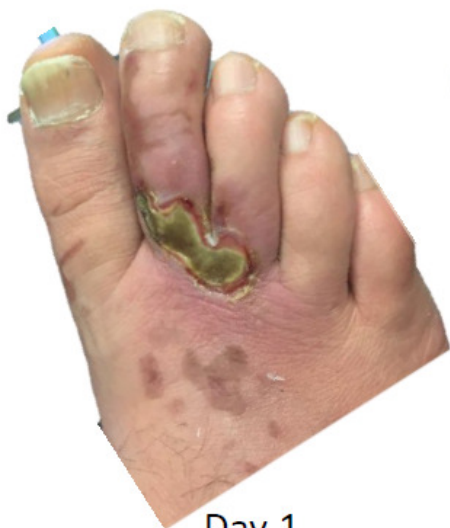Day 14

Photo Courtesy of:
DR. TRACEE SHORT,
BATON ROUGE REGIONAL
BURN CENTER, LA

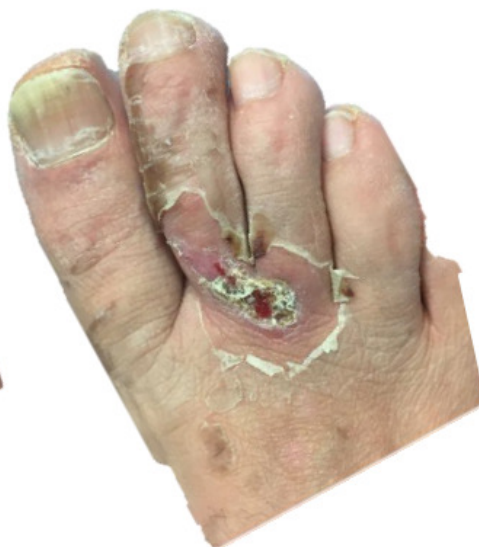Grease Burn

Burn Wounds

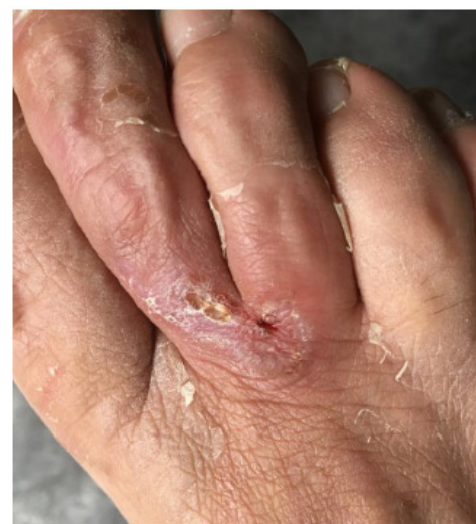Patient presented 7 days post grease burn.



Day 1



Day 11



Day 17

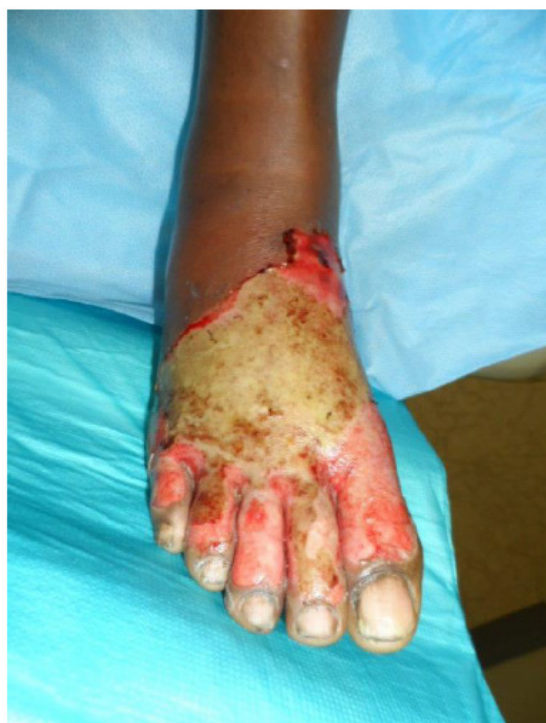Photo Courtesy of:
Joe Cornett RN, WCC, DWC
Sonoma Valley Hospital

27

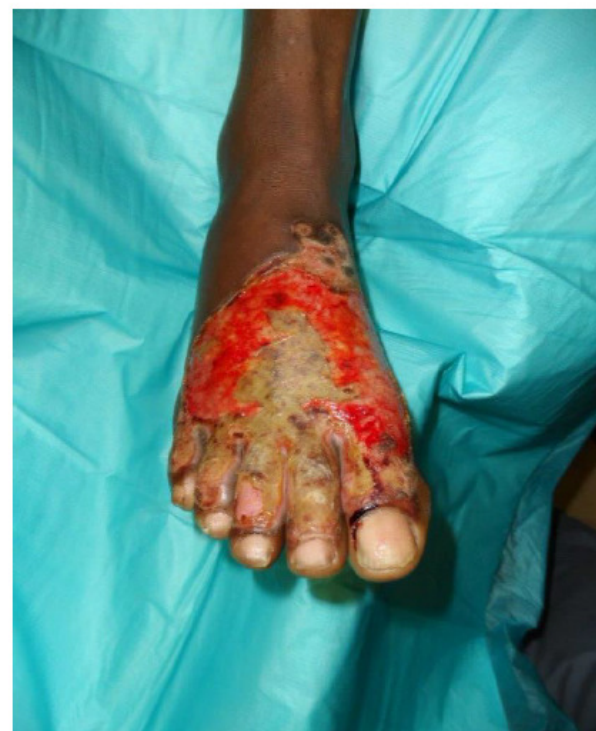Grease Burn

Burn Wounds

46 year old male presented 3 days post grease burn.



Day 1



Day 7

Photo Courtesy of:
DR. TRACEE SHORT,
BATON ROUGE REGIONAL
BURN CENTER, LA

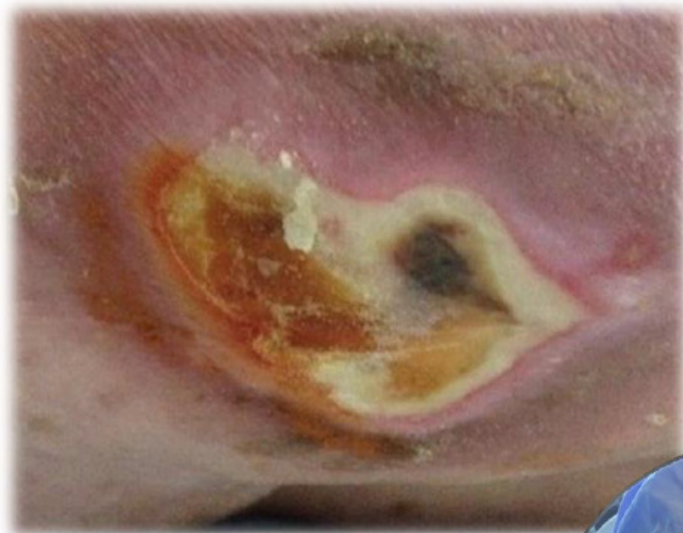28

PRESSURE ULCERS

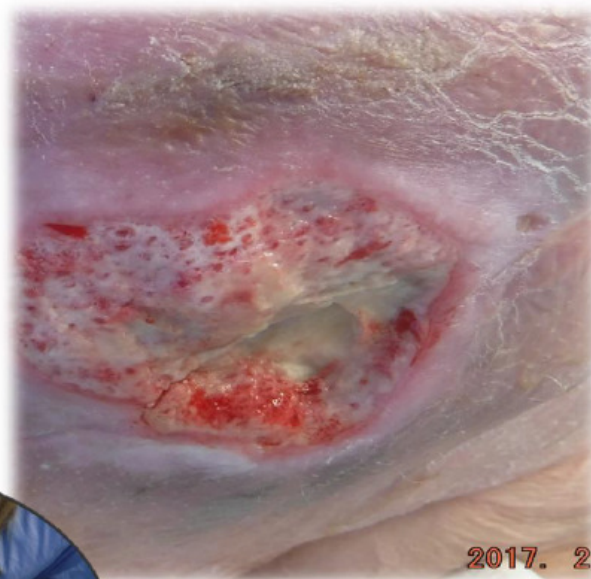PRESSURE ULCER

Pressure Ulcer

Age 75, PU due to Severe Kyphotic Back



Day 1



Day 6

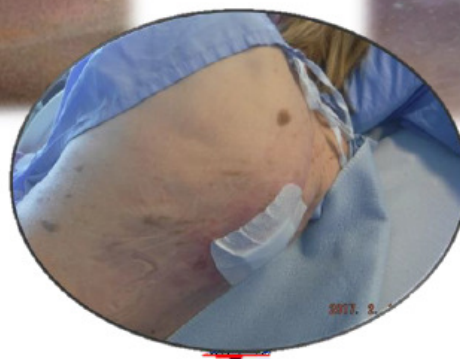


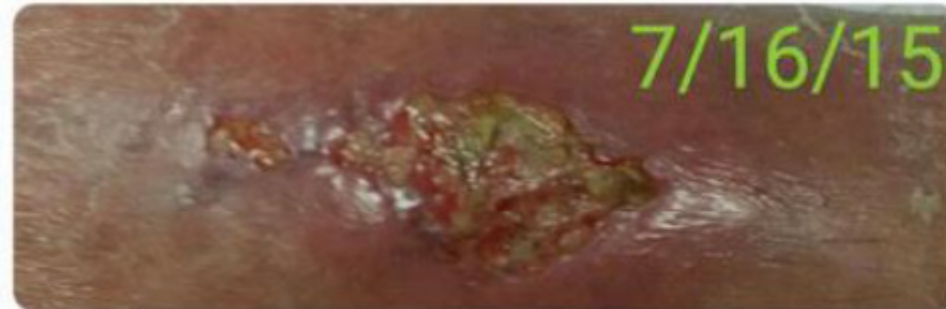Photo Courtesy of
Rosemary Hill RN, BSN, CWOCN, CETN (C)
VCH - Coastal - Lions Gate Hospital
Vancouver, BC Canada

VENOUS LEG ULCERS

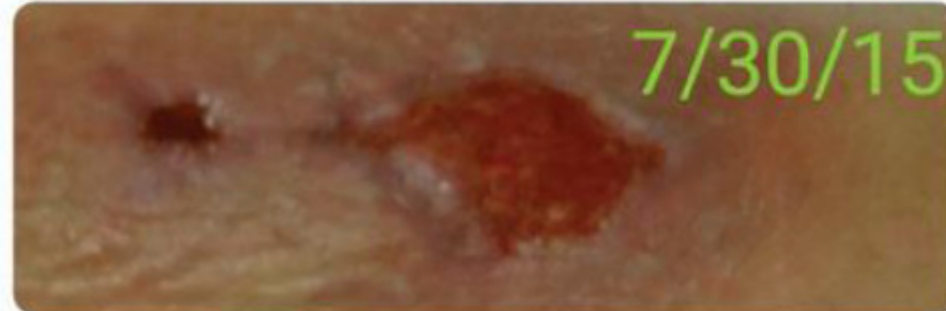
Left Anterior Shin

Venous Leg Ulcers

Day 1:



Day 14:



Day 27:

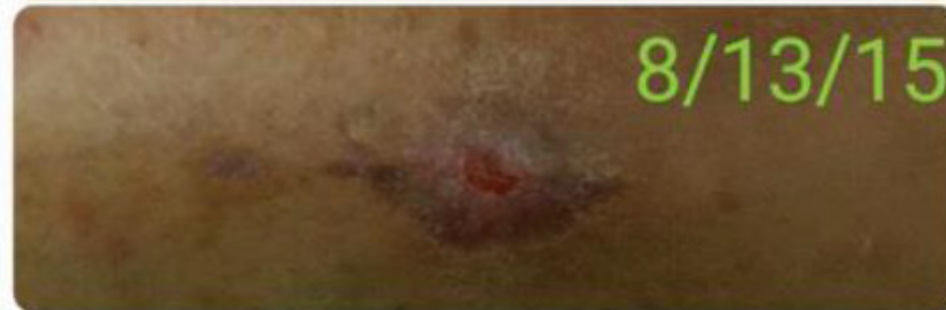

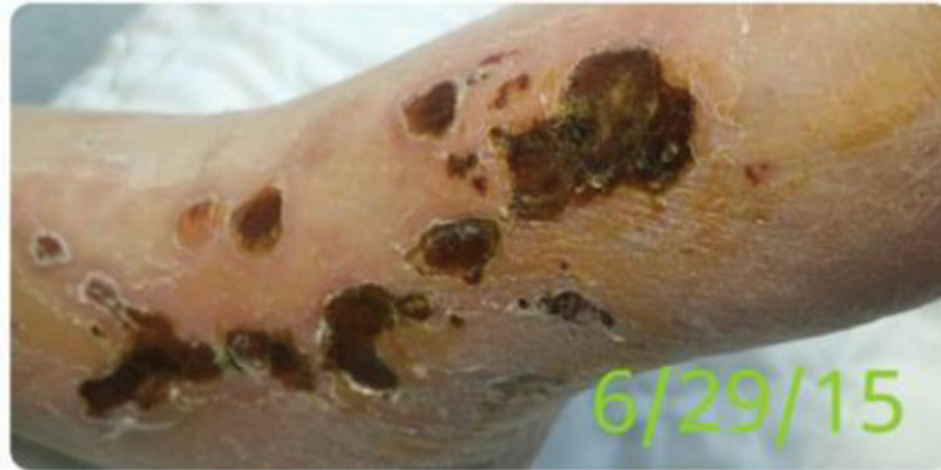Photo Courtesy of:

Windy Cole,
DPM Cleveland Regency East Hospital – Warrensville, OH

Left Lower Extremity

Venous Leg Ulcers

Day 1:



Day 8:

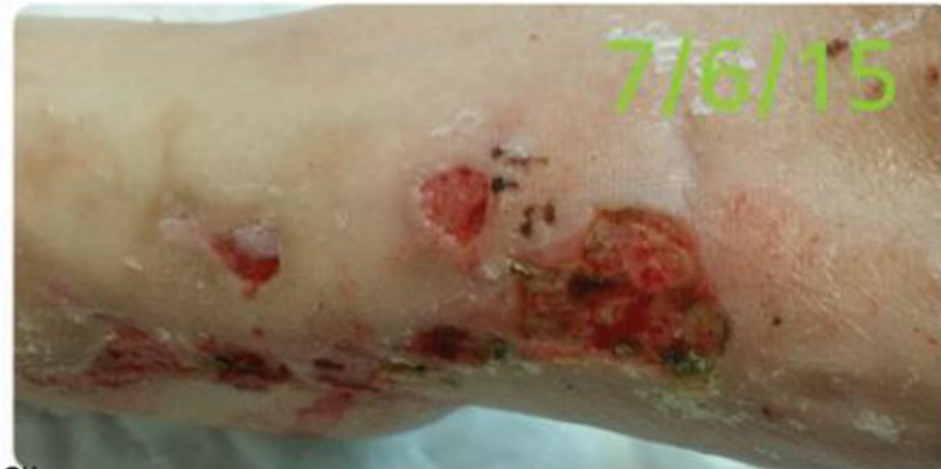

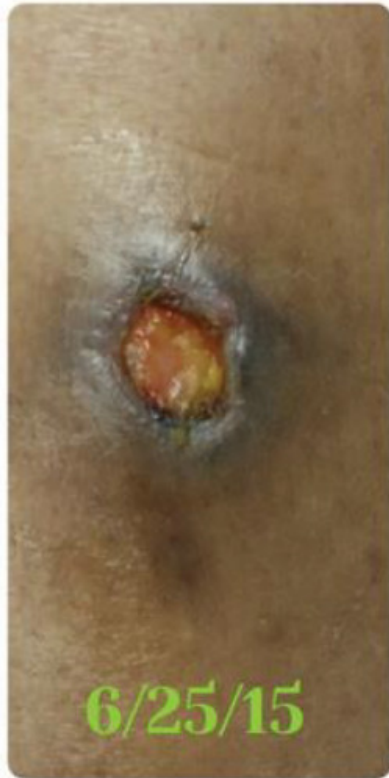Photo Courtesy of:

Windy Cole,
DPM Cleveland Regency East Hospital – Warrensville, OH

Left Anterior Shin

Venous Leg Ulcers

Day 1:

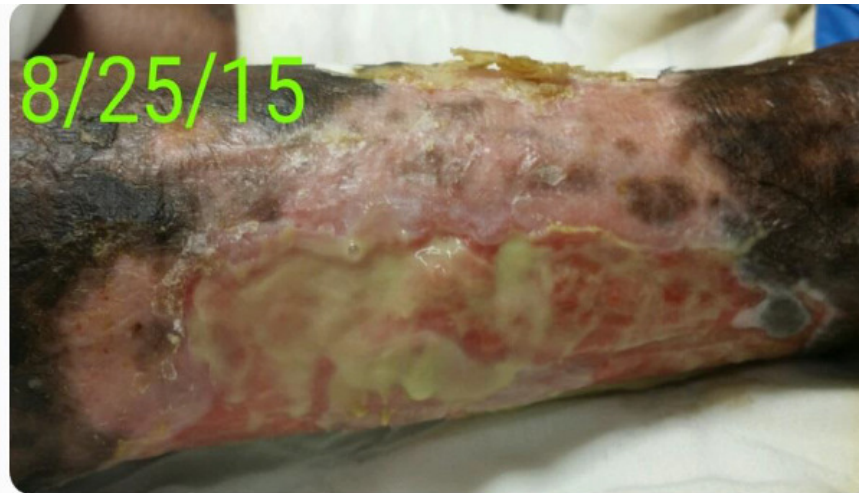


Day 8:

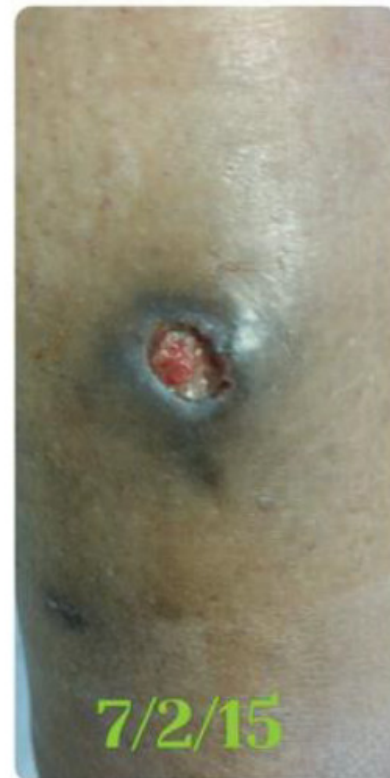

Photo Courtesy of:
Windy Cole, DPM
Cleveland Regency East Hospital – Warrensville, OH

Day 1



Day 7

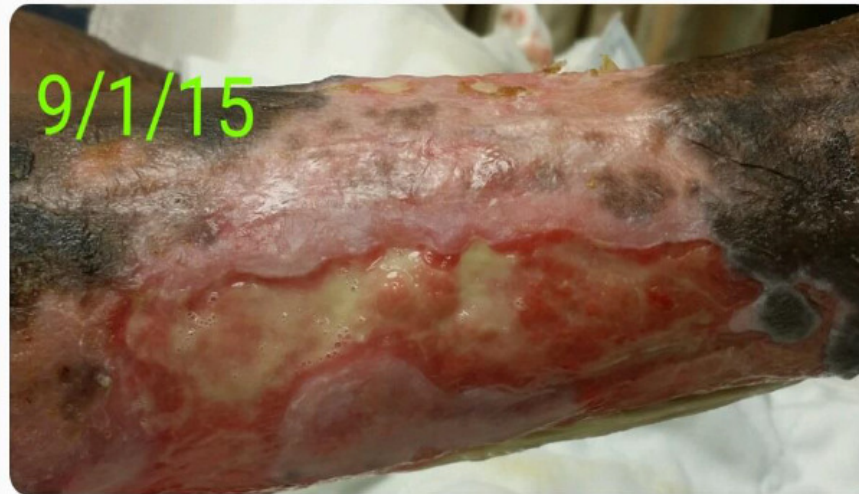


Photo Courtesy of:
Windy Cole, DPM
Cleveland Regency East Hospital – Warrensville, OH

VLU – Stalled Wound

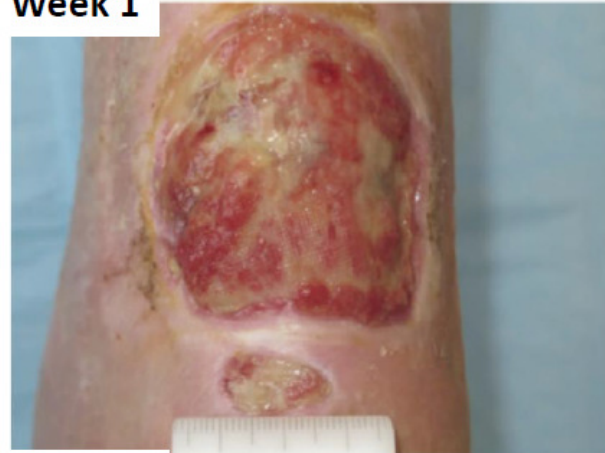Venous Leg Ulcers

- Age 62, VLU on posterior right ankle
- Comorbidities: diabetes, hypertension, hyperlipidemia, neuropathic pain & musculoskeletal pain
- Stalled for 10 months. Skin sub and compression used previously.
- CST applied 1-2 times per week under compression.

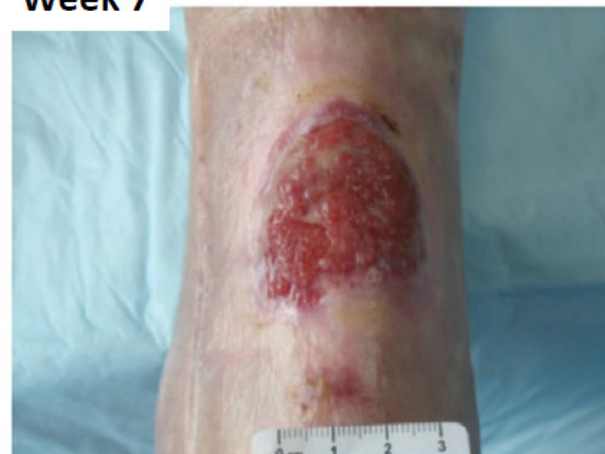69% reduction in wound size by week 7.

Photo Courtesy of:
Robert Kirsner, MD, PhD
University of Miami – Miami, FL

Week 1



Week 7



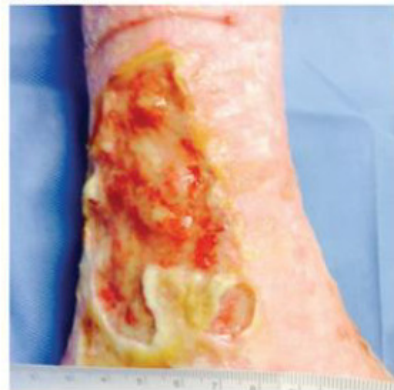6

VLU – Stalled Wound

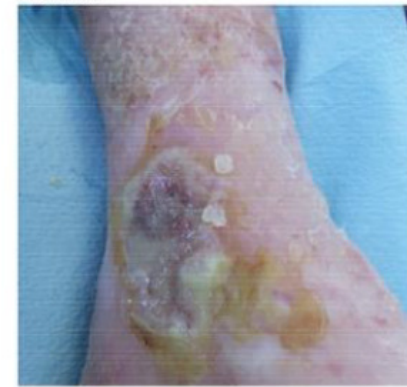Venous Leg Ulcers

- Age 84, VLU on left medial ankle and VLU on the left lateral ankle
- Comorbidities: hypertension, thyroid disease, chronic venous insufficiency, GERD, and osteoarthritis
- Stalled for 5 months prior to CST
- CST applied 1-2 times per week under compression

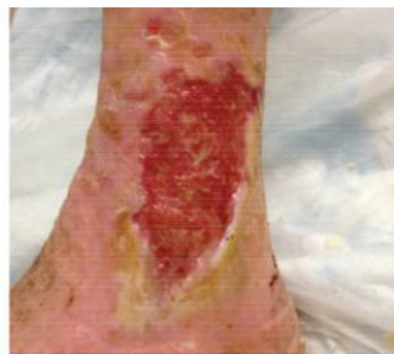Week 1
Medial



Week 15
Medial



Week 1
Lateral



Week 13
Lateral

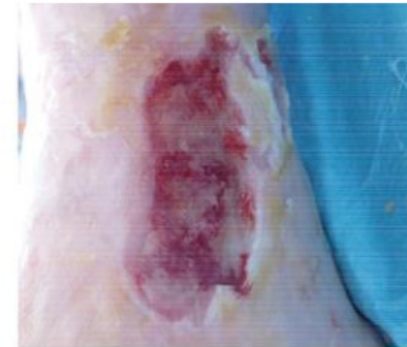
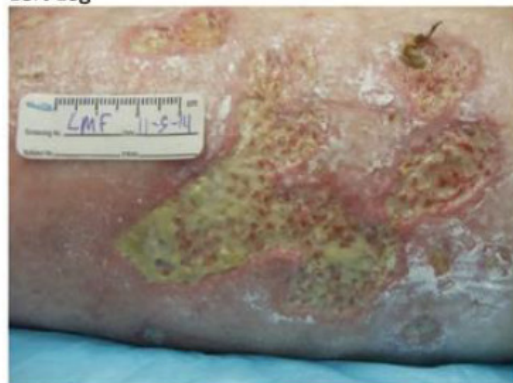


Photo Courtesy of:
Robert Kirsner, MD, PhD
University of Miami – Miami, FL

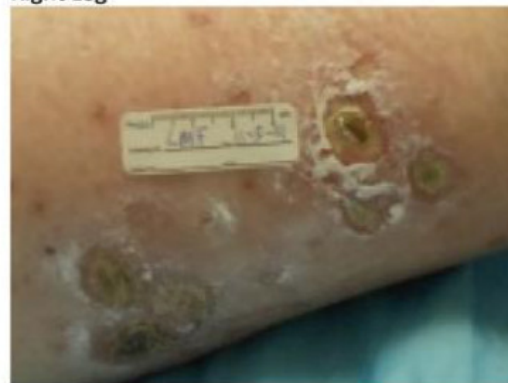VASCULITIS

Age 56, Multiple bilateral leg ulcers. Oral prednisone , weekly compression.
CST applied 1x per week. Wounds closed 12 weeks.

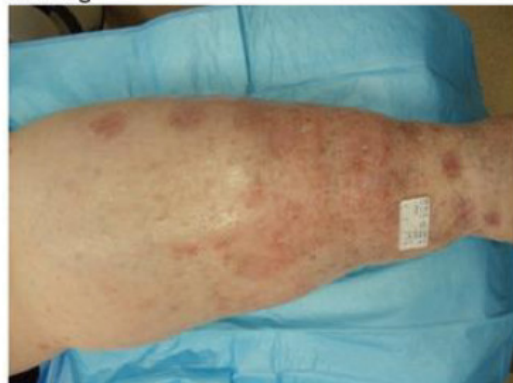November 5
Left Leg



Right Leg



March
Left Leg



Right Leg

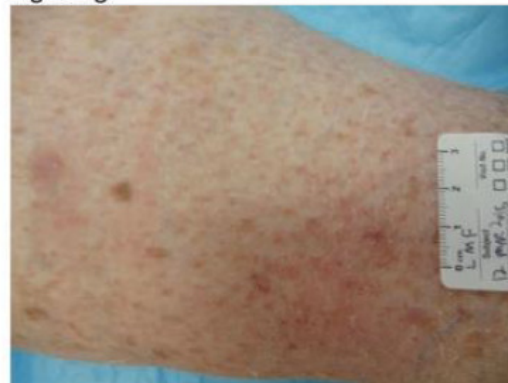

Photo Courtesy of:
Robert Kirsner, MD, PhD
University of Miami – Miami, FL

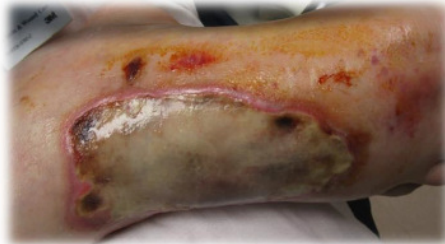DIABETIC FOOT

Diabetic Foot Ulcer with Exposed Tendon

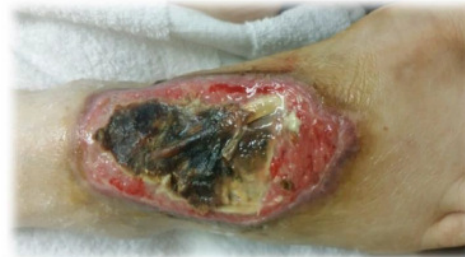Diabetic Foot
Ulcers

LIT066WC

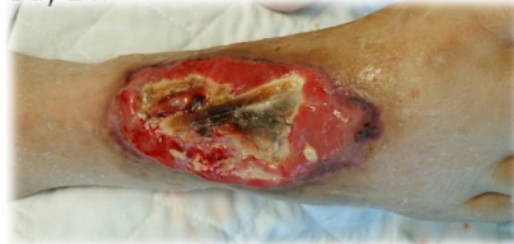Day 1:



Day 7:



Day 14:



Day 21:

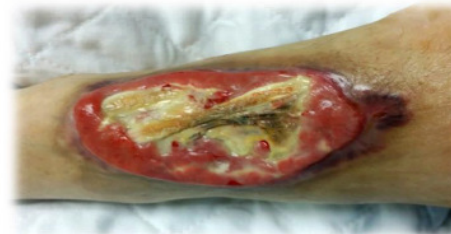

Photo Courtesy of:
Windy Cole, DPM
Cleveland Regency East Hospital – Warrensville, OH

Wagner Grade 3 ulceration of dorsum of the foot.

11x 6.4cm wound. DFU with hard eschar and slough. Exposed tendon and severe necrosis of the soft tissues of the foot. Patient refused surgical debridement.

After 1 week, odor was gone. Necrotic tissue decreased from 90 to 60% in 14 days. Granulation improved as the amount of eschar decreased.

After 21 days patient left LTAC, no follow up.

DFU – STALLED WOUND

-Age 63, DFU on right plantar
forefoot

Comorbidities: diabetes,
hypertension, hyperlipidemia,
and gangrene of right great toe
(reason for amputation)

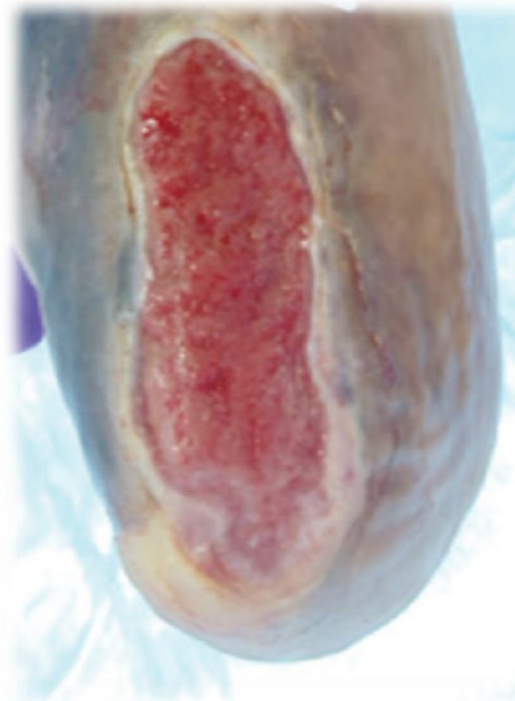17.28 cm x 7.2 cm with an area
of 124.42 cm².

Stalled for 7 months

CST applied weekly

Closed at 26 weeks

March 6



June 8

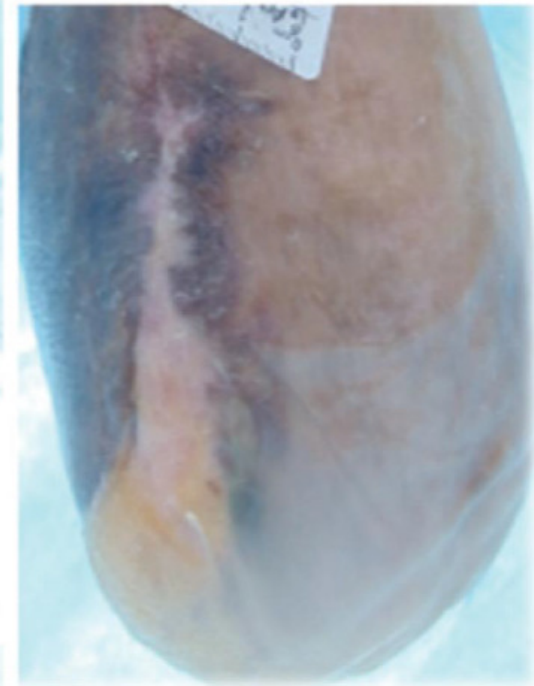


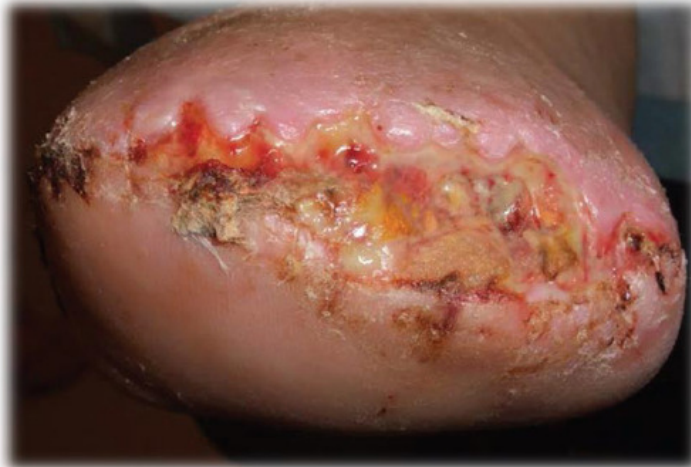Photo Courtesy of:
Robert Kirsner, MD, PhD
University of Miami – Miami, FL

METATARASL AMPUTATION

Diabetic Foot
Ulcers

Trans metatarsal amputation; comorbidity - diabetes

Day 1:



Day 28:

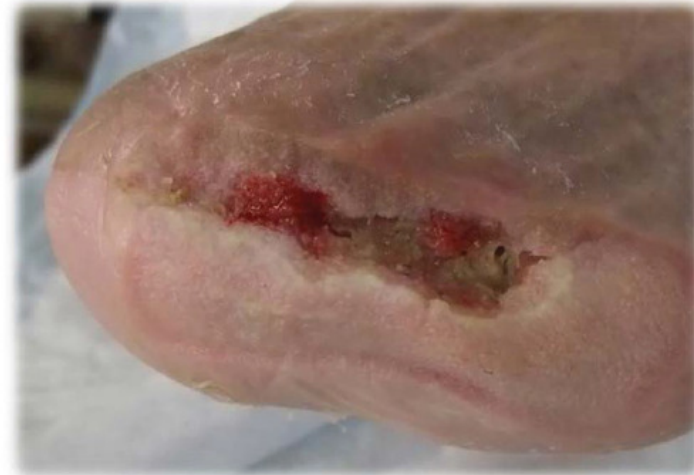

Photo Courtesy of:
Adam Landsman, DPM, PhD
Harvard Medical School – Cambridge, MA

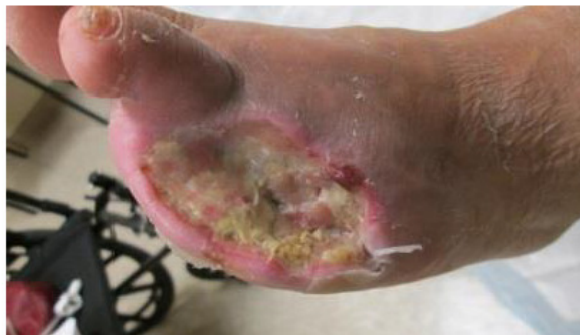14

DFU - TOE AMPUTATION

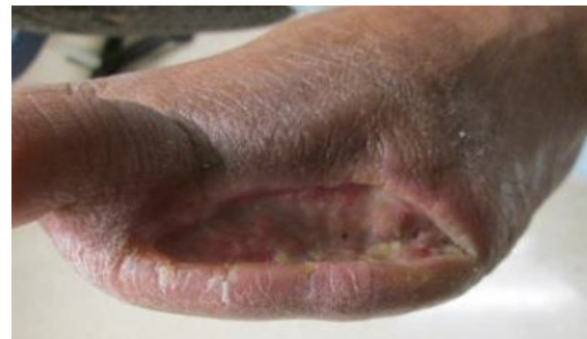Diabetic Foot
Ulcers

Age 52, Toe amputation, slow healing
Comorbidity: diabetes

Day 1:



Day 28:



Day 42:

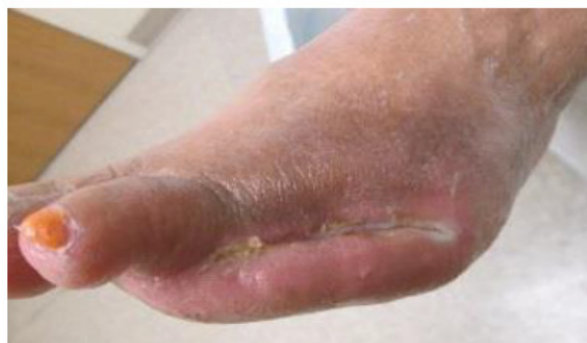

Photo Courtesy of:
Catherine Ratliff, PhD, NP, CWOCN
University of Virginia Health System -- Charlottesville, VA

15

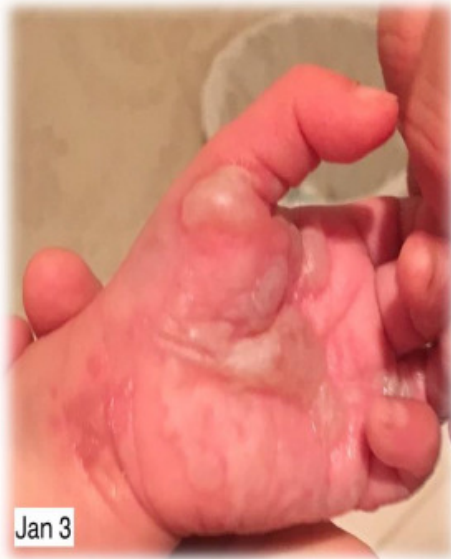PAEDIATRIC CASES

Paediatric Burn

Burn Wounds

» Age 10 months, Fell into fire pit. Burn to hand, deep partial thickness burn.

Day 1



Day 3



Day 24

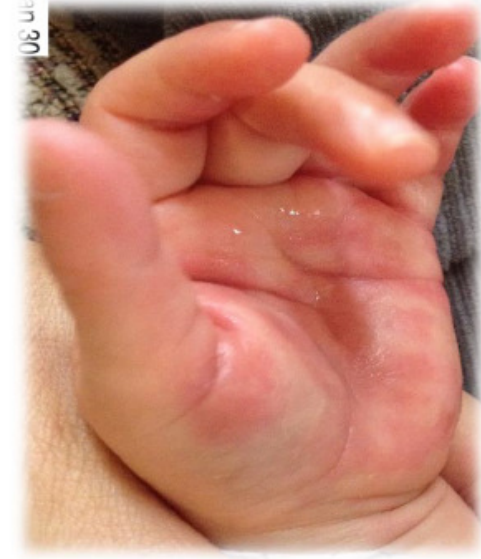
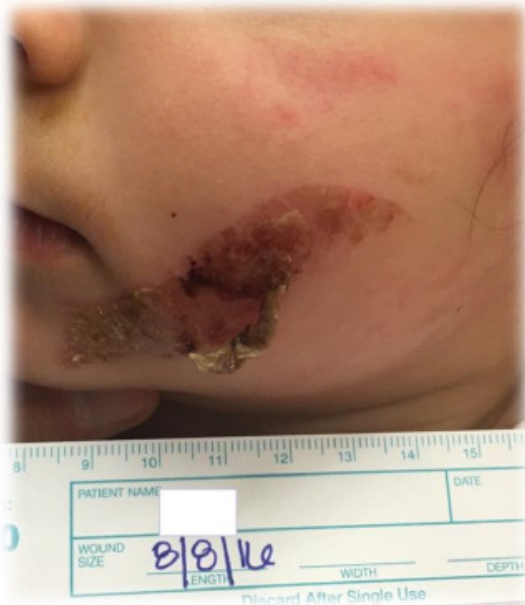
Photo Courtesy of:
Rene Amaya, MD, FAAP, CWSP
Health Bridge Children's Hospital – Houston, TX

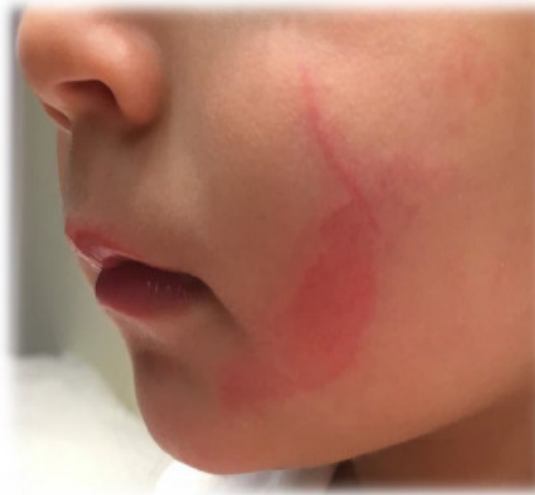Paediatric Burn

Age 2, 400o Curling Iron. Applied CST daily with foam dressing for 2 weeks.

Day 1



Day 7



Week 6 Follow Up

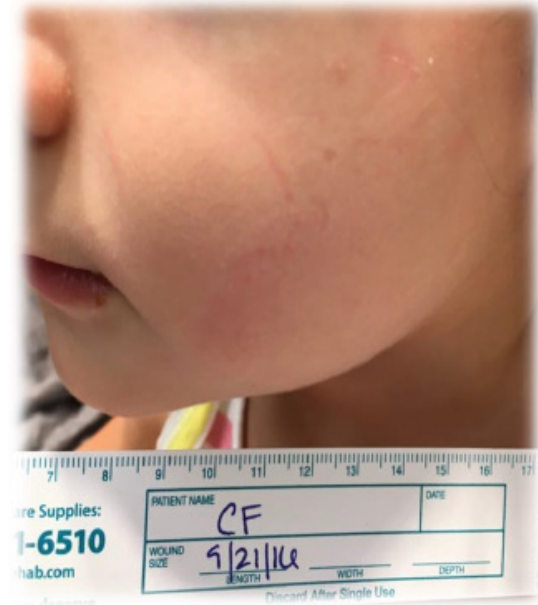

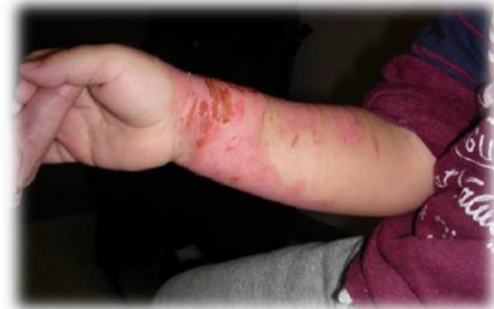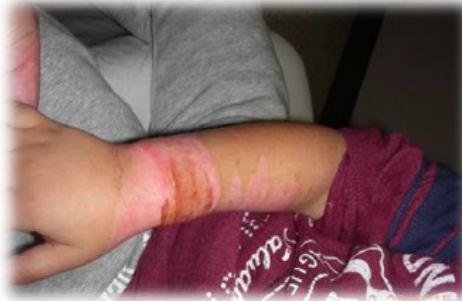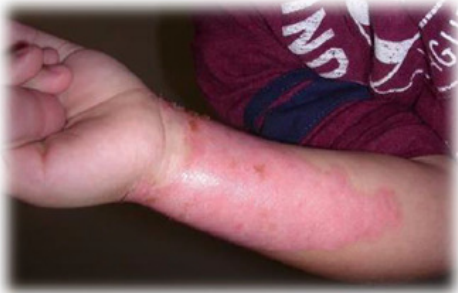Photo Courtesy of:
Rene Amaya, MD, FAAP, CWSP
Health Bridge Children's Hospital – Houston, TX

Paediatric Burn

Burn Wounds

Age 3, Scald burn to arm, 2nd Degree

Day 1



Day 25

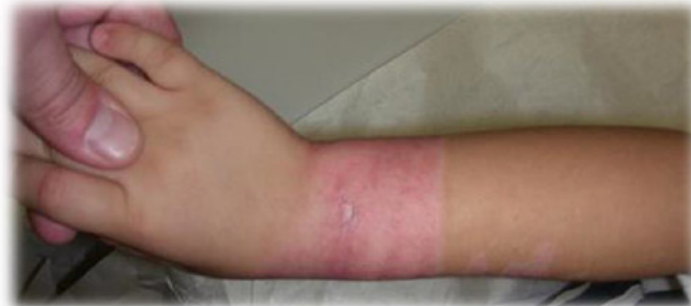
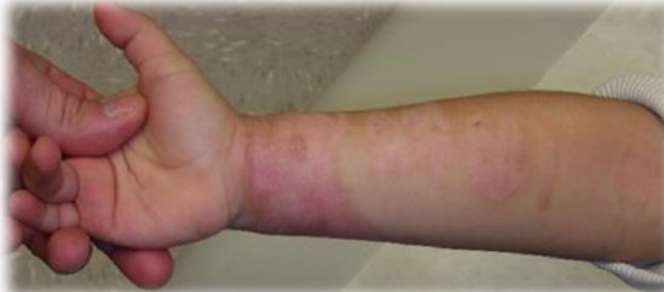
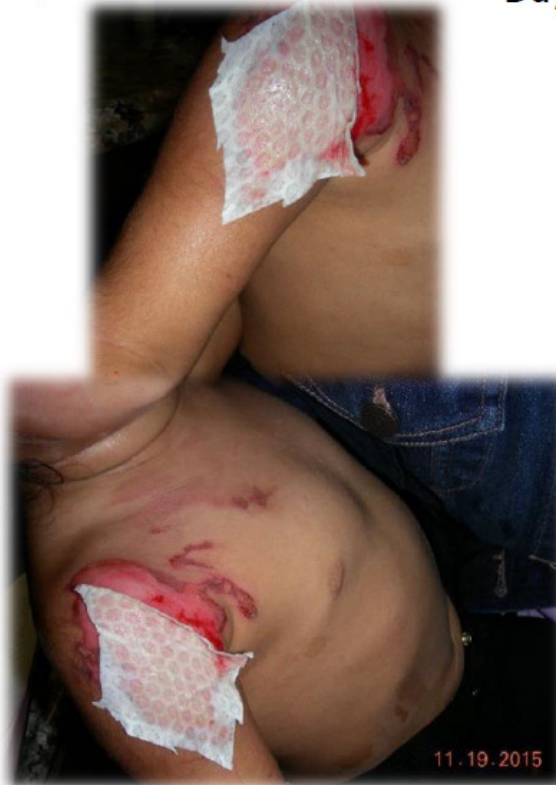Photo Courtesy of:
Farid Mozaffari, MD, FACS
Marshall University -- Huntington, WV

Paediatric Burn

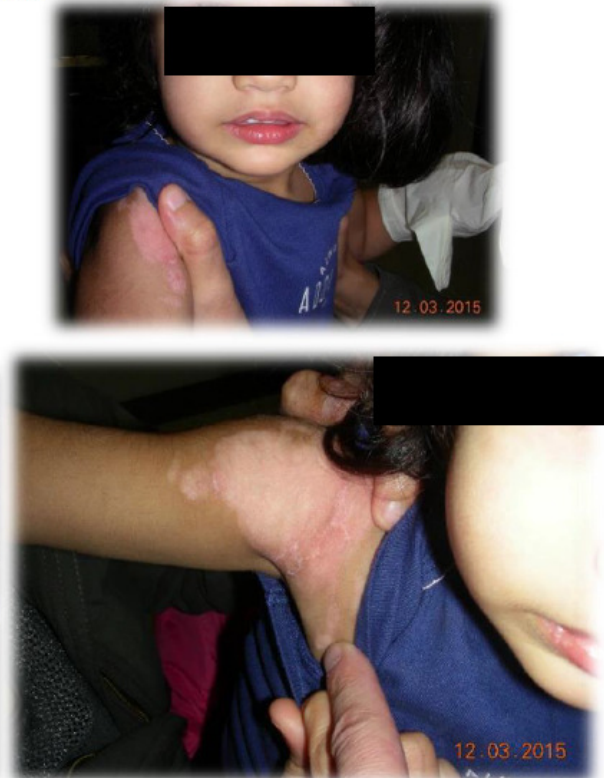Burn Wounds

Age 17 MO., Scald burn to shoulder

Day 1



Day 14



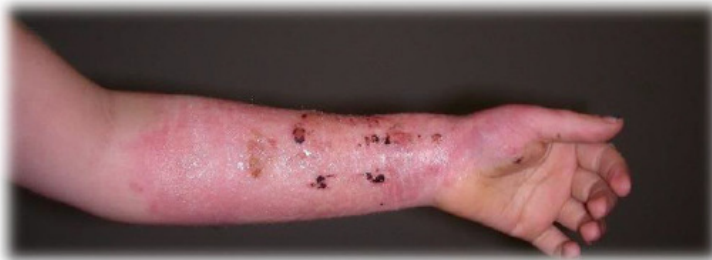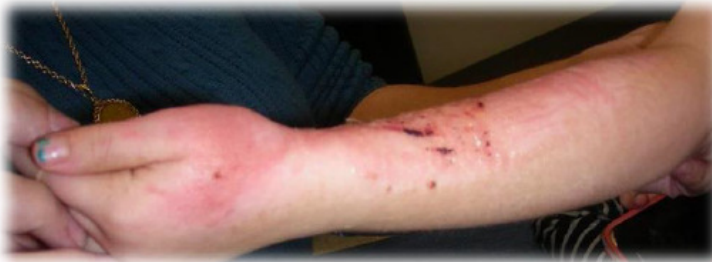Photos Courtesy of:
Farid Mozaffari, MD, FACS
Marshall University Huntington, VA

Paediatric Burn

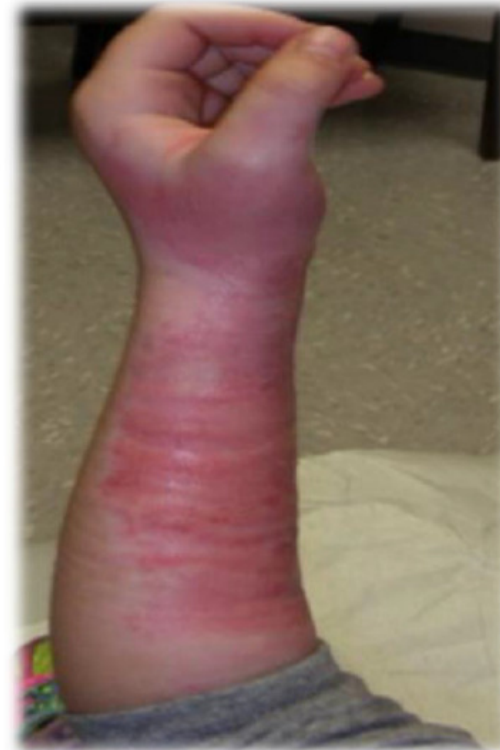Burn Wounds

Age 4, Scald burn to hand and arm

Day 1



Day 12



Photos Courtesy of:
Farid Mozaffari, MD, FACS
Marshall University Huntington, VA

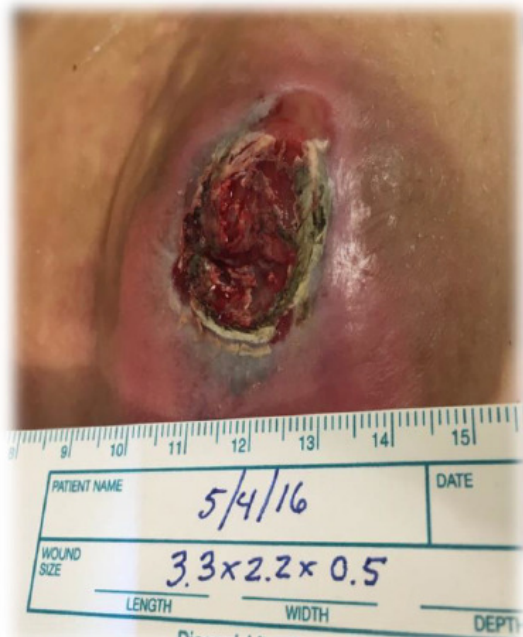23

PAEDIATRIC PRESSURE INJURY

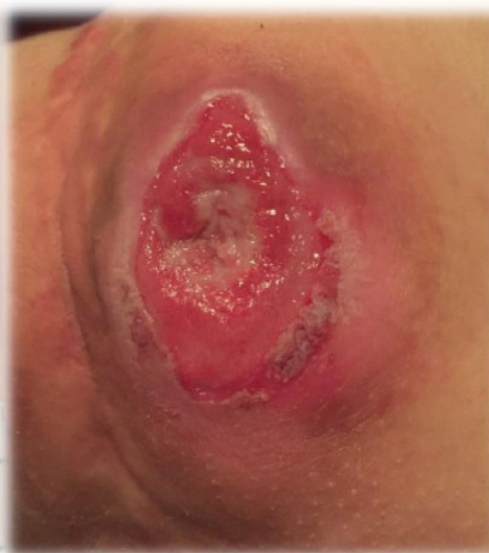Pressure Ulcer

Age 10, Spina bifida, Stage 3 pressure ulcer to lower back
Size: 3.3 x 2.2cm = 7.26cm² Depth – Deep crater with undermining adjacent soft tissue
Edges – Not attached Undermining- 100% 0.5cm Type: Adherent, soft black eschar

Day 1



Day 6



Day 13

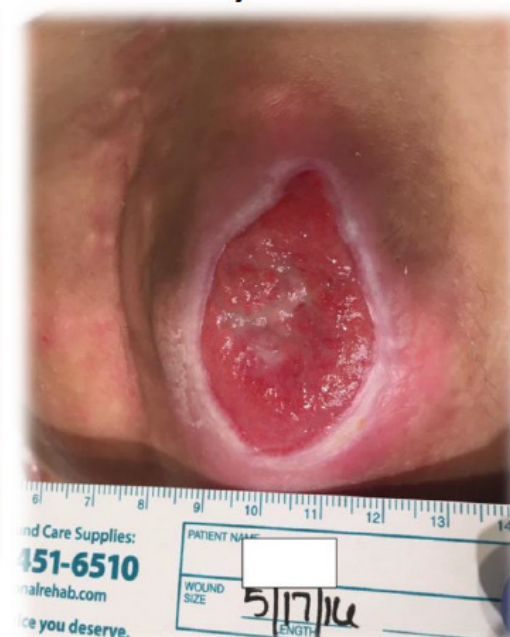

Photo Courtesy of:
Rene Amaya, MD, FAAP, CWSP
Health Bridge Children's Hospital – Houston, TX

17

Paediatric Necrotic Fungal Dermatitis

15 day old 24 week gestation. Cultures identified *Aspergillus Fumigatus*

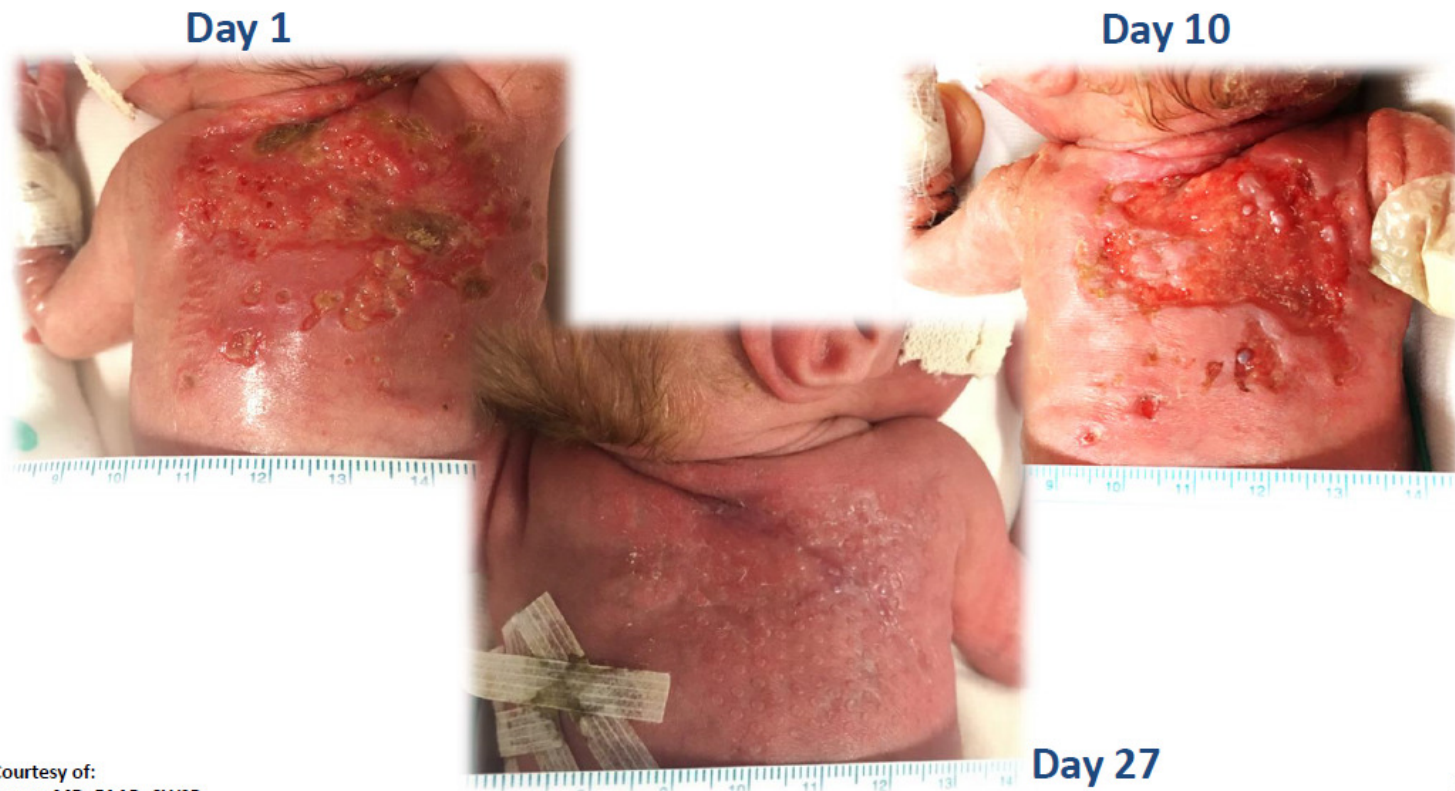

Photo Courtesy of:
Rene Amaya, MD, FAAP, CWSP
Health Bridge Children's Hospital – Houston, TX

16

Paediatric Necrotic Wound

- Cause of necrosis unknown
- 15% wound size decrease in 4 days
- 93% decrease in 13 days

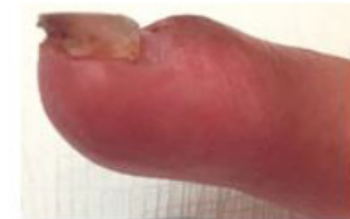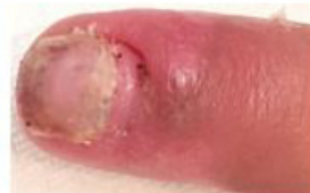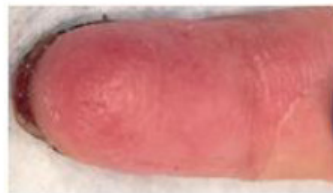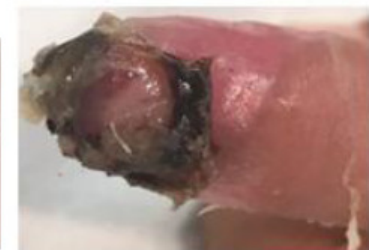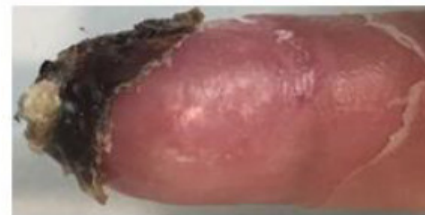
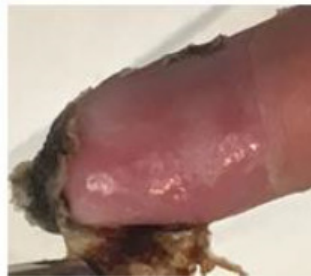
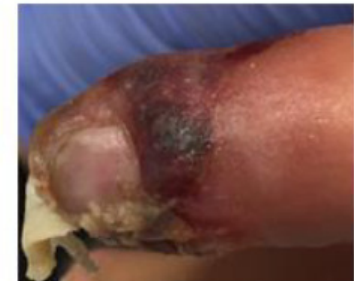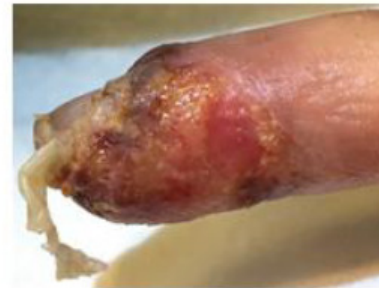


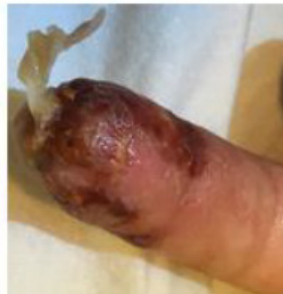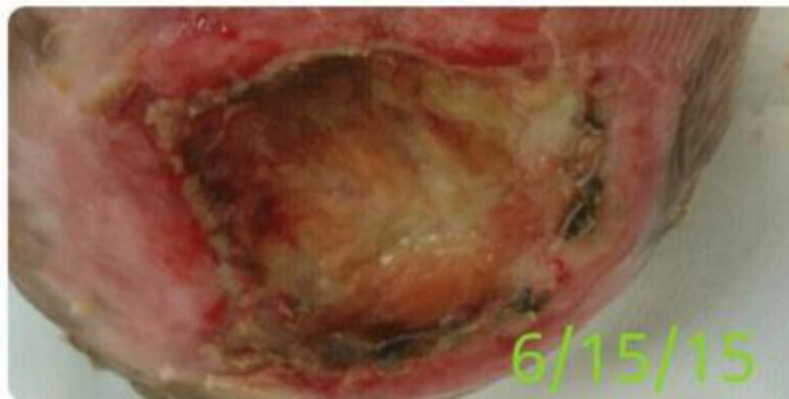
Photo Courtesy of:
Rene Amaya, MD, FAAP, CWSP
Health Bridge Children's Hospital – Houston, TX

OTHER WOUNDS

TRAUMA WOUND

Full thickness right heel trauma wound

Day 1:



Day 14:

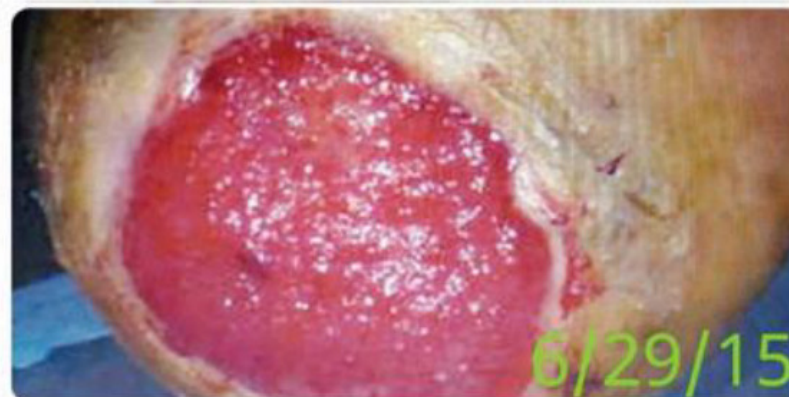
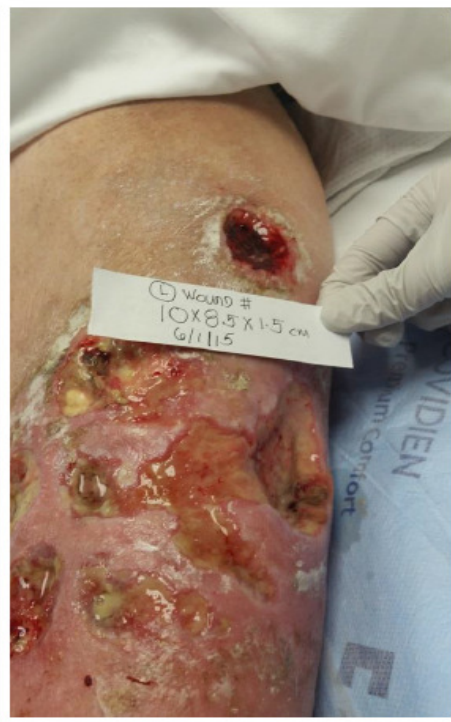
Photo Courtesy of:
Windy Cole, DPM
Cleveland Regency East Hospital – Warrensville, OH

PYODERMA GANGRENOSUM

Age 52, Complication to total colectomy.
Wounds closed by start of 3rd month

Day 1



Day 10

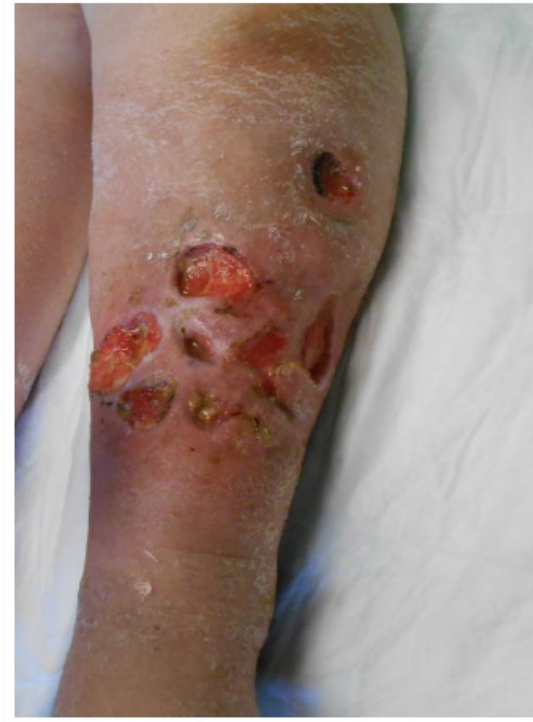

Photo Courtesy of:
Priscilla Grant, BSN, RN, HT, CWCN
St Josephs /Candler Health Savannah, GA

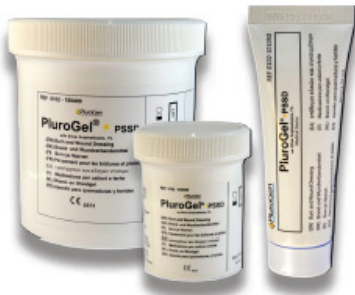Assortment

PLUROGEL



<u>Item No.</u>	<u>Item Description</u>	<u>Qty/Case</u>
0102-170050	PluroGel 50 g jar	24/case
0102-170400	PluroGel 400 g jar	6/case

PLUROGEL PSSD



<u>Item No.</u>	<u>Item Description</u>	<u>Qty/Case</u>
0102-100050	PluroGel PSSD 50 g jar	24/case
0102-101050	PluroGel PSSD 50 g tube	12/case
0102-100400	PluroGel PSSD 400 g jar	6/case

	Average Number of Dressings per Jar					
Jar Size	5cm x 5cm	10cm x 10cm	15cm x 5cm	4cm x 10cm	4cm x 20cm	4cm x 30cm
400g	160	40	18	100	50	33
50g	20	5	2	12	6	4



MEDLINE